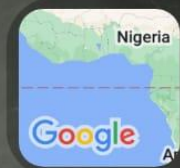

**FACILITIES FOR
INNOVATIONS
AT
GOVERNMENT DENTAL
COLLEGE & HOSPITAL,
AHMEDABAD**

List of Equipments

1.	Cone Beam Computed Tomography	Oral Medicine and Radiology
2.	3 D Printer	
3.	Endodontic Microscope	Endodontics
4.	Parallelometer	Prosthodontics
5.	Manual Milling Machine	
6.	Spot Welding Machine	
7.	Induction Casting Machine	
8.	Incubator	Oral Pathology
9.	Tissue Floatation Bath	
10.	Microtome	
11.	Hot Plate	
12.	Paraffin Bath	
13.	Tissue Processor	
14.	Well-equipped Forensic Odontology	
15.	Conscious Sedation Unit	Pedodontics
16.	Implant Kit	Periodontology
17.	Automated Hematology Analyzer	General Pathology
18.	Biochemistry Analyzer	

Oral Medicine and Radiology

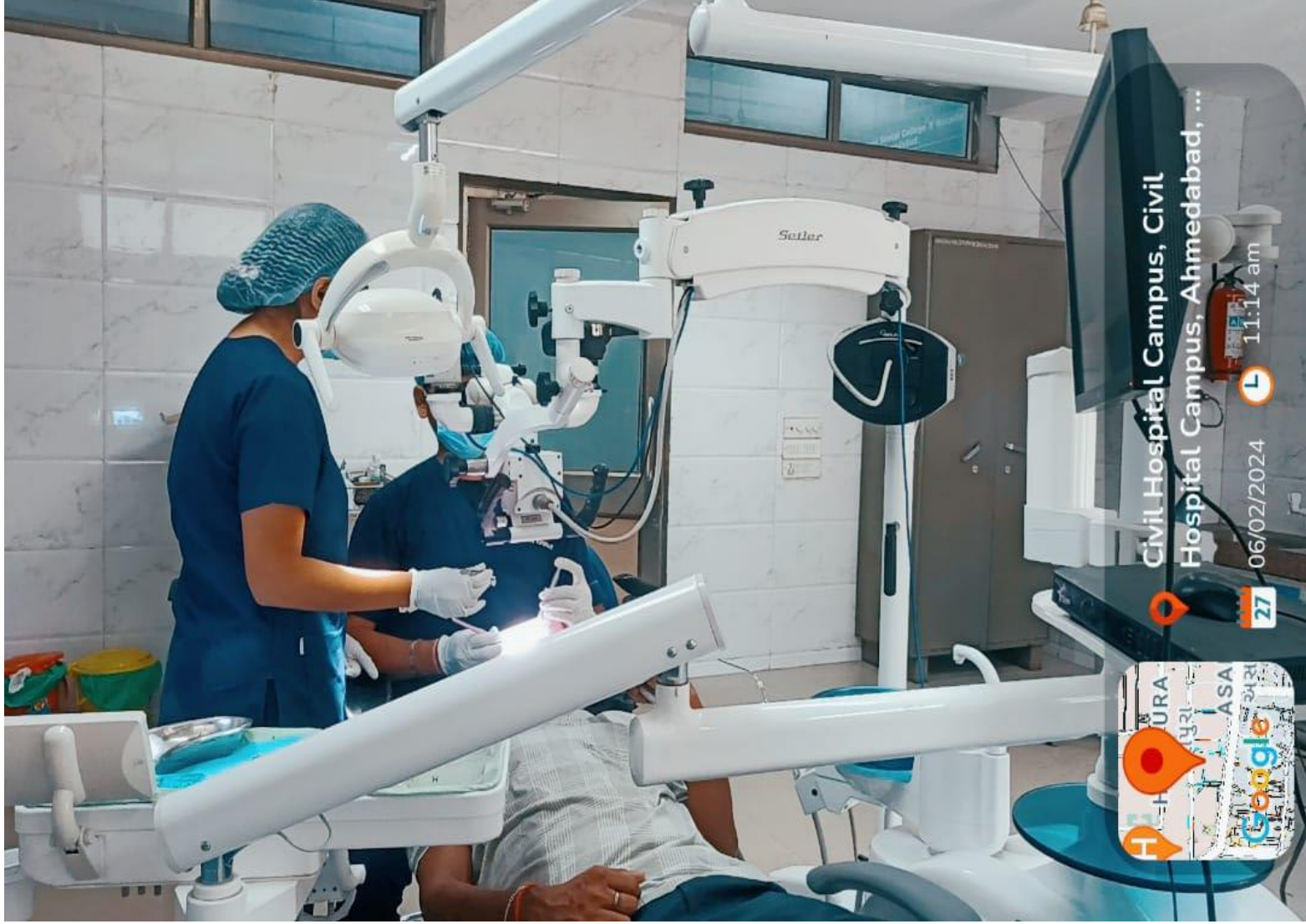

civil hospital compound, opp.
dental ward, Haripura, Asarwa, ...

27 27/02/2024 10:50 AM

Oral Medicine and Radiology





Prosthodontics

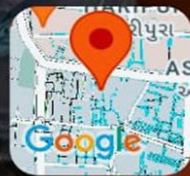




Civil Hospital Campus, Civil
Hospital Campus, Ahmedabad, ...

12/02/2024 12:01 PM





Civil Hospital Campus, Civil
Hospital Campus, Ahmedabad, ...



12/02/2024



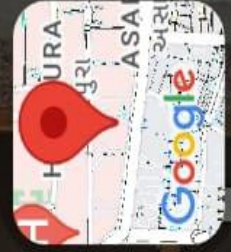12:01 pm

Oral Pathology





1, Civil Hospital Rd, Patel Society,
Asarwa, Ahmedabad, Gujarat 3...



05/01/2024 10:00 AM



27



GOVERNMENT DENTAL COLLEGE & HOSPITAL, AHMEDABAD.
Dept. of Oral & Maxillofacial Pathology

Oral Microbiology
SAMPLE COLLECTION AND HANDLING

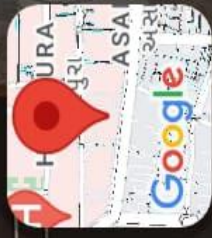
TYPES OF SAMPLE RECEIVED

HISTOPATHOLOGY	MICROBIOLOGY	CYTOLOGY
GUIDELINES	PROCEDURE	PROCEDURE

SAMPLE REJECTION CRITERIA

- 1. Falsified Specimens.
- 2. Incomplete, Labeled (Microbiology).
- 3. Incomplete Labeling of Histopathology.
- 4. Incomplete Specimens for Flow cytometry.
- 5. Incomplete Specimens for Parasitology.

1, Civil Hospital Rd, Patel Society,
Asarwa, Ahmedabad, Gujarat 3...



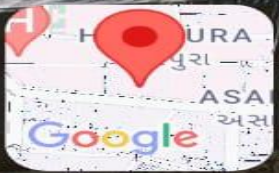10:00 AM

05/01/2024





TISSUE
PROCESSING
AREA



1, Civil Hospital Rd, Patel Society,
Asarwa, Ahmedabad, Gujarat 3...

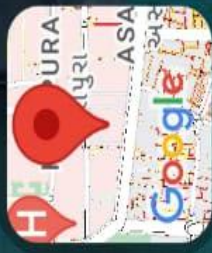
05/01/2024 23.0496
10:00 AM 72.60481



Civil Hospital Campus, Civil Hospital Campus, Ahmedabad, ...

11:14 AM

06/02/2024





"What a nightmare!...bodies as of negroes....blackened; heads carbonized; shrunk and reduced to nothing, but only the teeth remained."

Dr. OSCAR AMOEDO

Teacher of Forensic Odontology

Introduction
The age estimation committee was established in the year 2010. The committee members are engaged in the study of assessing the radiolar teeth, histological, and histological means. The dental age is assessed using clinical, radiographic, and histological means. The cases that require the estimation of dental age for legal purposes are usually the second premolar teeth under the PDL, but also lateral incisors, age verification cases under the Space Analysis of the PDL, crown case treatment, forensic, and identification cases under IAF, etc. The cases are registered under the IAF region of the institution and a case report is recorded.

In the case of a forensic victim of sexual assault, the dental examination is done in presence of a forensic physician. The current for clinical and radiographic contribution is obtained from the parent and from the guardian in the case of minors.

Forensic Odontology in GDCH Ahmedabad
A dedicated committee for forensic age estimation was formed in 2012. The members of the committee through their expertise in forensic odontology under the Indian Evidence Act of 1907.

Recent dental cases under IAF, Aug, 2023 are referred to dental age estimation.

Special reports and forensic opinion are issued from Forensic, Medical Department of the PDL for age estimation case assessment.

Special IAF cases, involving 1000 cases are referred to dental age estimation of forensic age estimation from forensic cases in the IAF of 2017-2023.

The committee members are engaged in the study of assessing the radiolar teeth, histological, and histological means. The cases that require the estimation of dental age for legal purposes are usually the second premolar teeth under the PDL, but also lateral incisors, age verification cases under the Space Analysis of the PDL, crown case treatment, forensic, and identification cases under IAF, etc. The cases are registered under the IAF region of the institution and a case report is recorded.

Microscopic and histological methods are used for age estimation (IAF, Ahmedabad 2017-2023).

Forensic and age estimation cases handled in IAF Ahmedabad

Dental Age Estimation Methods

Teeth are the biological markers of aging



Method

- Macroscopic / Clinical methods
- Microscopic / Histologic methods
- Radiographic methods
- Biostatistical methods

Type

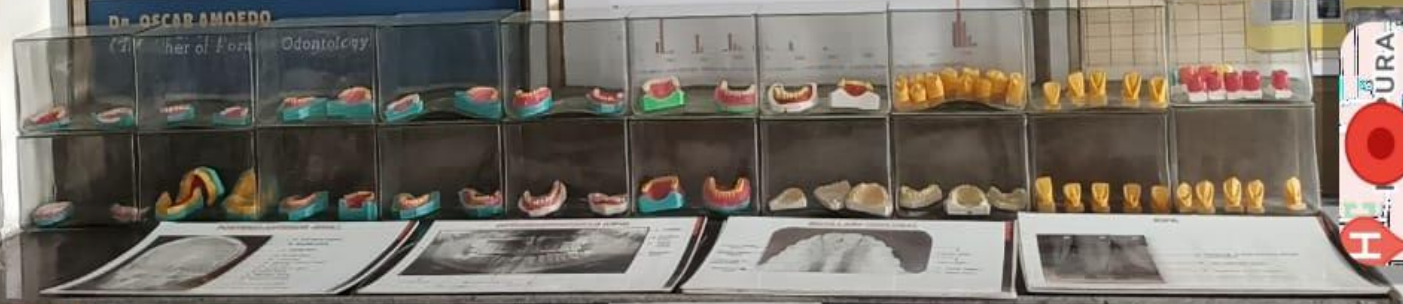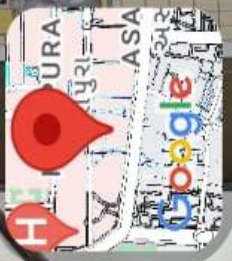- Atlas method
- Metric method
- Other methods

Civil Hospital Campus, Civil Hospital Campus, Ahmedabad, Hospital Campus, Ahmedabad, ...

11:14 AM

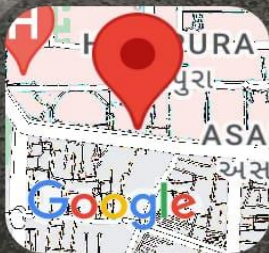
06/02/2024

27



MEDICO-LEGAL AGE ESTIMATION CASE FILES

Pedodontics



 13, Civil Hospital Rd, Kanti Lal Ki Chaali, Asarwa, Ahmedabad, ...

 27 05/12/2023  23.04937

 11:00 am  72.60467

Periodontology Implant Clinic



General Pathology



Automated Hematology Analyzer



Civil Hospital Campus, Civil Hospital Campus, Ahmedabad, ...

11:14 am



06/02/2024



27

